

**Northwest Community Healthcare  
Paramedic Program**

# **Introduction to ECG INTERPRETATION**

**Reading assignments:** This handout

**Education standards:**

**Monitoring devices:** Fundamental depth, foundational breadth within the scope of practice of the paramedic: Obtaining and using information from patient monitoring devices including (but not limited to): Continuous ECG monitoring

**Psychomotor skills:** Safely and effectively perform all psychomotor skills within the National EMS Scope of Practice Model AND state Scope of Practice at this level. Assessment: ECG interpretation

**OBJECTIVES:**

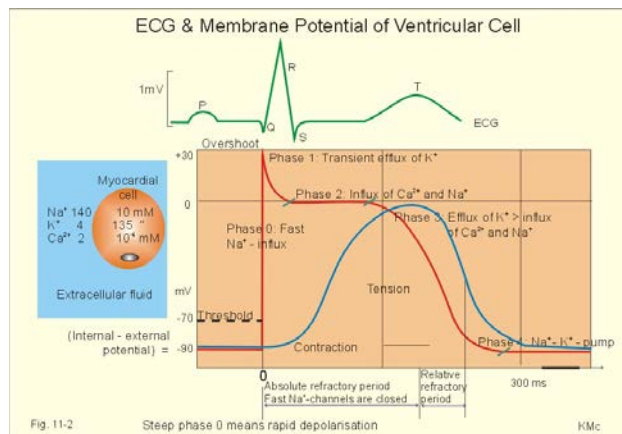
Upon completion of the assigned readings, class and homework questions, each participant will independently do the following with at least an 80% degree of accuracy and no critical errors:

1. Describe the purpose and limitations of ECG monitoring.
2. Define three electrical properties of heart cells.
3. Explain the electrical cardiac cycle including an analysis of electrolyte contribution to the process.
4. Identify and locate the major electrical conduction system structures and state their intrinsic pacing rates.
5. Describe the equipment that is used to monitor a cardiac rhythm.
6. Define a bipolar lead and describe how it differs from a 12-lead ECG.
7. Compare and contrast the current vectors that are monitored in the bipolar and limb leads.
8. Describe what type of information can and cannot be obtained from a bipolar lead.
9. Describe information obtained from the vertical and horizontal axes of the ECG graph paper.
10. Describe the markings on ECG paper and explain their significance.
11. State the time measurement of one small square and one large square on ECG paper.
12. Identify the isoelectric baseline and describe why a deflection is positive or negative in relationship to the baseline.
13. Explain the etiology and methods to troubleshoot ECG artifact.
14. Sequence the steps in analyzing an ECG rhythm strip.
15. Describe the normal parameters for the following aspects of an ECG rhythm strip: Rate, Rhythm, P waves, PR interval, and QRS complex duration
16. Describe two common methods for calculating heart rate on an ECG rhythm strip and the indications for using each method.
17. Describe the mechanisms of electrical impulse formation.
18. Given an ECG rhythm strip, identify the following:
  - P waves
  - QRS complexes
  - P-P intervals
  - R-R intervals
  - P-R intervals
  - J point and ST segments
  - T waves
  - isoelectric line
19. Describe different configurations of P waves, QRS complexes and their significance.
20. Given an ECG strip, describe the regularity, calculate the rate (atrial and ventricular) and determine the presence of P waves, the P-R interval and QRS duration.
21. Correlate the mechanical responses in the heart to the electrical tracing on the cardiogram.
22. Identify normal sinus rhythm on a 6 second strip.

## NCH Paramedic Program ECG INTERPRETATION

### I. Depolarization and repolarization

- A. Cardiac electrical cells are able to generate and conduct electrical impulses that result in depolarization (electrical activation), contraction (systole), and repolarization (recovery) of the myocardial cells.
- B. These impulses are the result of a flow of positively charged ions back and forth across the semipermeable cardiac cell membrane.
- C. Electrical charges across the membrane are regulated primarily by sodium ( $\text{Na}^+$ ) and calcium ( $\text{Ca}^{++}$ ) outside the cell and potassium ( $\text{K}^+$ ) inside the cell.
  1. The cycle of ion shifts continuously changes the electrical charge inside the cell, resulting in periods of activity (depolarization) and periods of rest (repolarization).
  2. Membrane channels open and close in response to a stimulus (electrical, chemical, or mechanical). They are also affected by the concentration gradient. Charged particles also move in response to an electrical gradient. Positively charged ions are attracted to negatively charged ions and vice versa. This results in an unequal distribution of charged particles across the cell membrane with an electrical difference between the intracellular and extracellular regions.
  3. **At rest, the electrical charge inside the cell is more negative than outside.**
    - a. When the resting cell is **polarized**, no electrical activity is occurring.
    - b. This phase is represented on the ECG as an isoelectric (flat) baseline.
    - c. Once the cell threshold is met, the membrane permeability changes. Sodium rapidly enters the cell through fast channels, calcium enters through slower channels, and potassium exits.
      - (1) Pacemaker cells are slow channel cells and are therefore depolarized predominately by **calcium**.
      - (2) Myocardial (worker) cells are fast channel cells, and are therefore depolarized predominately by **sodium**.
    - d. The inside of the cell now becomes more positive and results in cell **depolarization**. Muscle contraction occurs in response to calcium entry.
    - e. Once depolarization is complete, potassium reenters the cell and sodium exits, returning the inside of the cell to its resting or more negative charge. This recovery phase is **repolarization**.
    - f. The movement of the electrical current can be detected by skin electrodes and are recorded as waves or deflections on graph paper. This electrical tracing is called an **electrocardiogram or ECG**.

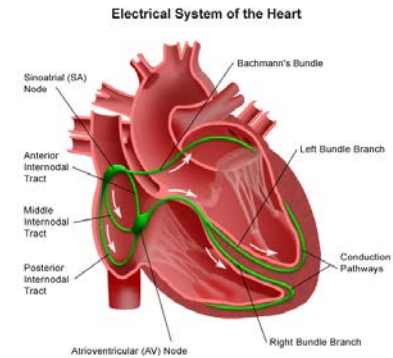


## II. Electrical conduction system

- A. The electrical conduction system generates and conducts electrical impulses along specialized pathways through the atria and ventricles causing them to contract after stimulation.
- B. Impulses are transmitted through the heart six times faster through the electrical conduction system than through muscle alone.

### C. Sequence of normal conduction

1. Sinoatrial (SA) node
2. Intra-atrial (internodal) pathways
3. Atrioventricular (AV) node
4. Bundle of HIS
5. Bundle branches
6. Purkinje fibers



### D. SA node

1. Located in the wall of the right atria near the inlet of the superior vena cava.
2. Intrinsic pacing rate: **60-100** per minute in a rhythmic fashion
3. Usually the **dominant pacemaker** of the heart. These cells repolarize the fastest, thus they have the highest level of automaticity. The pacemaker with the fastest rate will generally control the heart rate.
4. If the SA node fails to generate electrical impulses at its normal rate or the conduction is interrupted (blocked), pacemaker cells in other sites can assume control (**escape rhythms**), but at slower rates.
5. The farther the pacemaker site is from the SA node, the slower the rate.

### E. Interatrial and internodal tracts

1. The electrical impulse is conducted almost simultaneously to the left atrium via Bachman's bundle and through the right atrium through internodal tracts.
2. The atria must depolarize and contract simultaneously for a normal sequential heart beat

### F. AV node

1. Atrial impulses come back together at the AV node (AV Junction), located in the lower right atrium near the interatrial septum.
2. It provides the **ONLY** normal conduction pathway between the atria and ventricles.
3. AV node functions
  - a. Slows conduction of the impulse 0.08 seconds to allow time for the atria to contract and empty into the ventricles (atrial kick) before the ventricles contract. This delay is represented on the ECG as the flat line portion of the PR interval.
  - b. Can serve as an escape pacemaker if the SA node fails to pace at 60-100. **The intrinsic firing rate of the AV node is 40-60 beats per minute.**
  - c. When the atria are firing too rapidly (A-fib or flutter), the AV node may block some of the impulses from being conducted to the ventricles, thus protecting the ventricles from dangerously fast rates.

### G. Bundle of His

1. Also known as the common bundle
2. After delay in the AV node, the impulse travels rapidly through the Bundle of His.
3. These fibers are located at the top of the interventricular septum.

H. **Bundle branches**

1. The Bundle of His divides into the right and left bundle branches in order to rapidly send the electrical impulse to the bottom of the ventricles.
2. Because the left ventricle is relatively larger than the right, the left bundle branch further divides into the left anterior and left posterior fascicles.

I. **Purkinje fibers**

1. The terminal branches of the bundle branches are the Purkinje fibers. This network of fibers conducts the wave of depolarization to all ventricular myocardial cells causing the ventricles to contract from the bottom up.
2. They rapidly conduct the impulse at a normal rate of 0.04-0.10 seconds.
3. They may also become an escape pacemaker at 20-40 beats per minute.

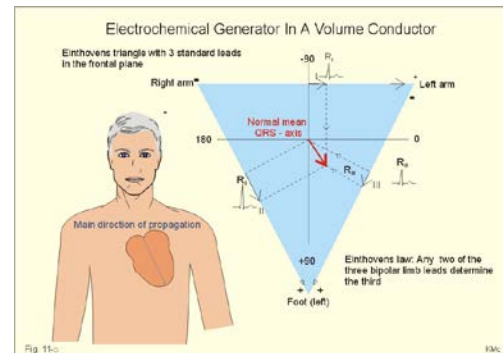
J. **Ectopic beats:** Means displaced. Depolarization occurs from cells other than the normal pacemaker cells. Ex: PACs; PJs, PVCs.

III. **ECG monitoring**

A. The body acts as a conductor of electrical current. The ECG is a graphic representation of multicellular electrical activity as sensed by electrodes placed on the body surface.

B. **Purpose**


1. To record two basic electrical processes: depolarization and repolarization
2. Bedside monitoring allows continuous observation of the heart's electrical activity and is used to identify dysrhythmias (disturbances in rate, rhythm or conduction. It can also be used to evaluate the effects of therapy.



C. **Equipment**

1. Electrodes
2. Monitor/defibrillator

D. ECGs can provide many "electrical views" of the heart's activity by monitoring voltage changes of cells underneath the electrodes. Each "view" is called a **lead**.



After the current is detected by electrodes attached to the skin, it is amplified, displayed on a monitor screen (oscilloscope) and can be recorded on ECG graph paper as waves and complexes.

E. A single (**bipolar**) lead is used for monitoring rhythms using a **3 or 4 leadwire system**.

1. The one lead ECG rhythm strip can reveal information about impulse formation, rhythm disturbances and conduction disturbances. It does not reveal information about the presence or location of an infarct, axis deviation or chamber enlargement, right to left differences or impulse formation.
2. If 3 electrodes and 3 leadwires are used: 1 electrode is placed on the right shoulder. This lead is usually white and is marked RA for right arm. It is the negative electrode.
3. 1 electrode is placed on the left shoulder. This lead is black and is marked LA for L arm. It is the positive electrode.
4. 1 electrode is placed on the left lower rib cage (8<sup>th</sup> intercostal space, left midclavicular line). This lead is usually red and is marked LL for left leg. This electrode provides the ground lead.

5. Collectively, these are called the **bipolar limb leads**. They form Einthoven's triangle.

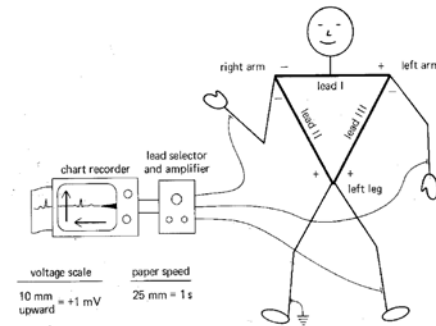
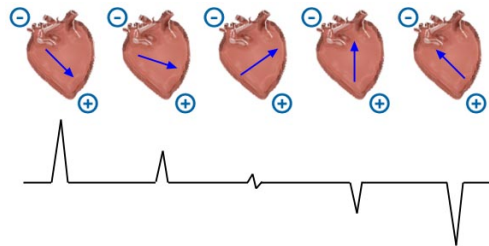


Figure 5-2 Einthoven's electrocardiographic conventions.

6. As long as the wave of depolarization or repolarization is traveling toward the positive electrode, the voltage will be + and there will be a positive deflection on the ECG tracing.
7. The voltage may be negative (downward deflection) indicating that the impulse was moving toward the negative electrode, away from the positive electrode.

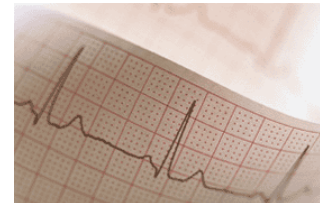


8. A waveform having both a positive and a negative component is called **biphasic**.  
**Isoelectric line:**

9. No deflection (isoelectric line) indicates either an absence of electrical impulse or impulse moving perpendicular to the electrodes.

10. Because the impulse is usually traveling toward the positive electrode in Lead II, the waves should all be upright.

11. You can monitor limb leads I, II, or III by adjusting the lead selector on the monitor. The most common monitoring lead is Lead II.



12. Although you cannot monitor chest (**precordial**) leads ( $V_1$ - $V_6$ ) with a 3 or 4 lead system, you can monitor modified chest leads which provide similar information. To monitor any of these leads, move the LL lead to the appropriate position for the chest lead you want to monitor and turn the leads selector on the monitor to Lead III.

13. This can also be done by placing the negative lead on the left 2<sup>nd</sup> intercostal space, the positive lead to the right of the sternum at the 4<sup>th</sup> intercostal space and the ground lead at the 8<sup>th</sup> intercostal space on the right.

14. **Unipolar or augmented limb leads** are aVR, aVL, and aVF and will be discussed with the 12 lead ECG content.

15. **12 lead ECG – brief introduction**

a. Provides many "views" of the heart

- (1) Leads I, II, III
- (2) Leads aVR, aVL, and aVF
- (3) 6 precordial leads

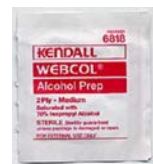b. **Advantages of a 12 lead**

- (1) Reduces the door to perfusion time in those candidates eligible for immediate reperfusion therapy.
- (2) ECG changes may disappear after treatment of ischemia in the field and before arrival at the ED. This is not a problem if the 12 lead was performed with the first set of vital signs.
- (3) If the patient has an underlying QRS co-founder (LVH or LBBB) the prehospital ECG can be used as a baseline to identify new changes.
- (4) May help triage patients to the most appropriate medical facility.
- (5) May reveal a RV infarct that needs to be treated differently.

F. **Methods to improve ECG signal**

1. Avoid placing electrodes over bony prominences, large muscle masses, areas with dense body hair or any place that prevents the electrode from close adherence to the skin.

2. Prep skin based on condition. If dry and flaky, wipe briskly with a dry towel or washcloth to remove dead skin cells. If extremely diaphoretic, wipe with an alcohol pad to dry thoroughly for better adhesion.



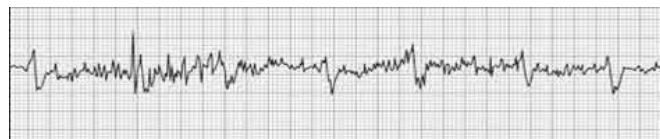
3. Inspect electrodes for open packaging, dried or discolored gel, expiration dates.

4. **Causes of poor signal/tracing**

- a. Excessive hair: Clip thick hair with scissors or electric trimmer before placing electrodes or part the hairs and seat the electrode firmly on skin.
- b. Diaphoretic patient
- c. Dried gel on electrode
- d. Poor electrode placement
- e. Loose electrodes
- f. Disconnected lead wire
- g. Bad wires

5. **Causes of artifact**

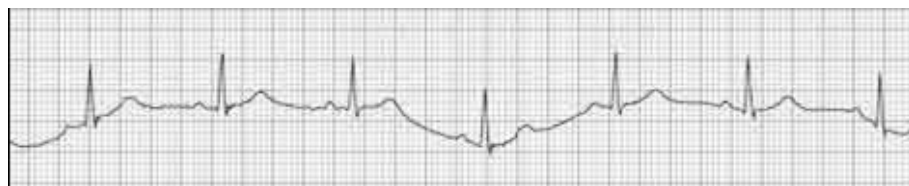
- a. Patient movement; seizure activity; muscle tremors



- b. Broken lead wire or patient cable
- c. Electrical interference - **60 cycle interference** seen when multiple electrical pieces of equipment are used in the same room or equipment is improperly grounded, there are loose connections or exposed wiring. The artifact looks like a continuous series of fine, even, rapid spikes.
- d. Equipment malfunction

6. **Wandering baseline**

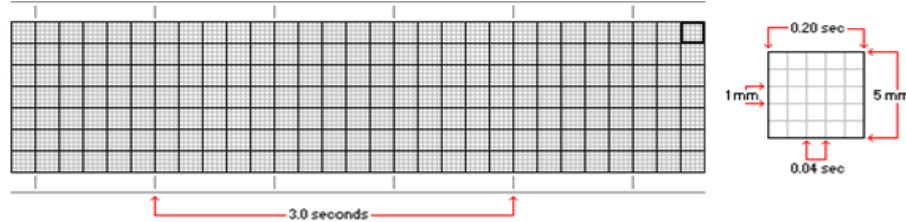
- a. Exaggerated respiratory movements
- b. Seen in patients with respiratory distress (COPD)
- c. Avoid placing electrodes over accessory muscles (anterior chest wall) in these patients. Put leads on top of shoulders if necessary.





IV. **ECG graph paper**

- A. Standardized to allow comparative analysis of ECG wave patterns
- B. Paper moves past a stylus at a constant, standard speed. Standard ECG machine moves paper at 25 small squares per second.
- C. **Graph paper markings:** Intersecting grids of vertical and horizontal lines divide the paper into small and large squares depending on the boldness of the lines.



1. **Time measurements**

- a. Vertical lines, every 5<sup>th</sup> line is bold
- b. **1 small square = 0.04 sec**
- c. **1 large square (5 small squares) = 0.20 sec**
- d. 5 large boxes = 1 second
- e. **30 large boxes = 6 seconds**
- f. 300 large boxes = 60 seconds
- g. At the top of the paper are time markings every 3 seconds. One needs a minimum of a 6 second strip for analysis. If no markings are present, count 30 large boxes.

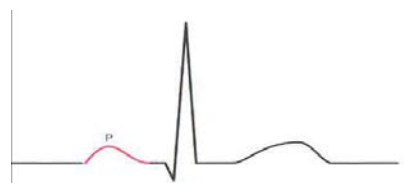
2. **Voltage measurements**

- a. Horizontal lines
- b. Measure up or down from isoelectric line
- c. 1 small box = 1 millivolt or 1 mm
- d. The size of the wave deflection will depend on the voltage or amplitude of the electrical current flowing toward the individual pole.
- e. Low voltage refers to complexes that are less than 5 mm total amplitude in the limb leads and 10 mm in the precordial leads.
- f. **Causes of low amplitude**
  - (1) Mis-set ECG monitor gain
  - (2) Pericardial effusion (tamponade)
  - (3) Infiltrative diseases
  - (4) Large amounts of lung volume
  - (5) Large amounts of pleural fluid
- g. If voltage is too low to interpret, turn up the gain on the monitor to increase the size of the tracing.

V. **Waveforms, intervals, segments and complexes**

A. **P Wave**

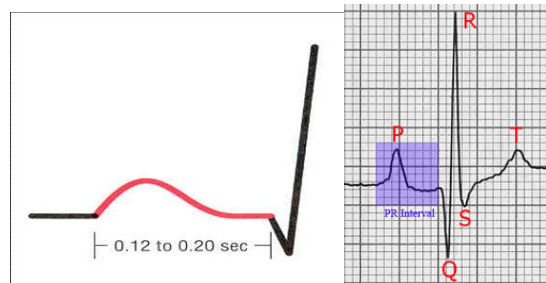
- 1. Usually the first deflection of the electrical cardiac cycle.
- 2. **Indicates that atrial depolarization has taken place.**
- 3. The wave begins as the deflection leaves the baseline and ends when the deflection returns to baseline.



4. Normal P waves are small, rounded, positive (upright), and look the same in Lead II with an amplitude between 0.5 mm and 2.5 mm and a duration of 0.10 seconds or less.
5. There should be 1 P wave for each QRS complex.
6. More than 1 P wave per QRS indicates a conduction disturbance through the AV node such as 2<sup>nd</sup> degree or 3<sup>rd</sup> degree heart block.
7. **Abnormal P waves may indicate the following:**
  - a. The impulse traveled through damaged or abnormal atrial tissue.
    - (1) A tall, pointed P wave indicates atrial enlargement secondary to pulmonary disease or congenital heart disease.
    - (2) A wide, notched P wave is seen in left atrial enlargement secondary to valvular heart disease or hypertensive heart disease.
  - b. The electrical impulse originated in a site outside of the SA node. This may produce P waves that are abnormal in size, shape or direction. Example: P waves may be inverted in Junctional complexes. In some ectopic rhythms, P waves may be absent.

#### B. PR interval

1. Time from the beginning of atrial depolarization to the beginning of ventricular depolarization.

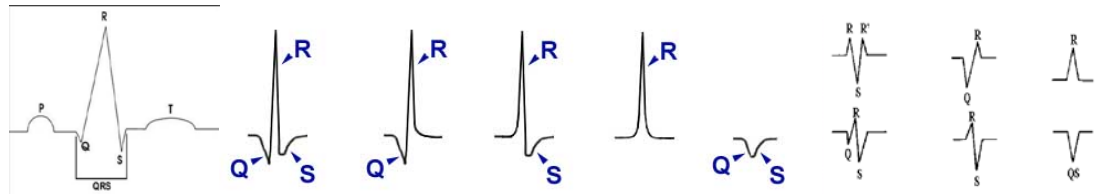


2. This represents the time it takes for the impulse to leave the SA node and to travel through the atria, the AV node, the bundles branches and the Purkinje network.
3. The interval is measured from the first deflection of the P wave to the first deflection of the QRS complex.
4. **A normal PR interval is 0.12 - 0.20 seconds.**
5. **The PR interval may be shorter** if the impulse was conducted through an abnormal (accessory or faster than normal) pathway that bypasses the AV node and bundle of His or if the impulse originated in a site close to or in the AV junction (junctional rhythms).
6. **The PR interval may be longer** if the impulse is abnormally delayed traveling through the AV node. A long PR is also associated with aging and may be the first clue to conduction system disease. Other causes include hyperkalemia and the administration of drugs like digoxin, quinidine, and procainamide (Pronestyl).

#### C. QRS complex

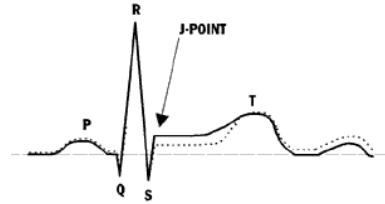
1. **Represents ventricular depolarization.**
2. The QRS complex is usually composed of a three wave deflection. It may have many shapes and all 3 waves are not always present.
  - a. Q wave: First negative deflection\* after the P wave
  - b. R wave: First positive deflection\* after the P wave or Q wave
  - c. S wave: First negative deflection following an R wave





3. Whatever the combination of waves, the complex is still called the QRS complex. If the entire QRS is negative, it is technically termed a QS complex because R waves are always positive.

4. It is measured from the first deflection from baseline either up or down. The end of the QRS occurs at the junction between the QRS complex and the ST segment where the last wave of the QRS complex begins to flatten out (become horizontal) into the ST segment. This is called the *junction* or **J point**.



Elevation or depression of the ST segment makes measuring the QRS more complicated.

5. The normal (narrow) QRS is upright in Lead II with a duration **0.04- 0.10 seconds**.

6. The abnormal or wide QRS has a duration of 0.12 seconds or greater.

7. It is also possible to have more than 1 R wave and more than 1 S wave. The second R wave is termed R prime and the second S wave is termed S prime. To be labeled separately, the wave must cross baseline. A wave that changes direction, but does not cross baseline is called a *notch*.

8. **An abnormally wide QRS complex may indicate the following:**

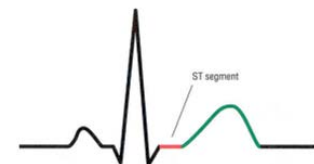
- a. A block in the conduction of impulses through one of the bundle branches (right or left bundle branch block or BBB).
- b. An electrical impulse that arrives early at the bundle branches before they have time to repolarize causing the impulse to be conducted abnormally (aberrant ventricular conduction).
- c. The electrical current is conducted from the atria to the ventricles through an abnormal conduction pathway that bypasses the AV node and bundle branches (preexcitation syndrome).
- d. The electrical impulse originated in the ventricles and had to travel through abnormal pathways, taking longer than normal
- e. Electrolyte abnormality (hyperkalemia) or the administration of certain drugs causing QT prolongation (quinidine, procainamide, tricyclic antidepressant overdose, toxic doses of Lidocaine etc).
- f. Paced rhythm: Look for a pacer spike, wide & bizarre QRS and HR consistent at 60-70
- g. Prior cardiac surgery
- h. Normal variable

9. Tall R waves are associated with ventricular enlargement

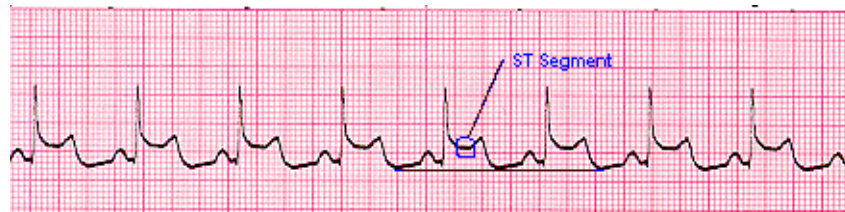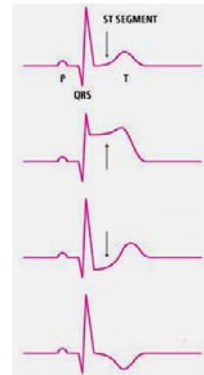10. Very small or low R waves are seen with obesity, emphysema, hypothyroidism, pericardial effusions, extensive MI, and myocardial fibrosis.

D. **ST segment**

1. Represents the end of ventricular depolarization and the beginning of ventricular repolarization.

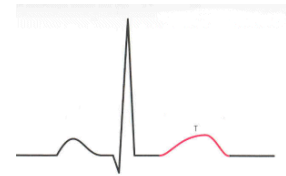


2. It begins at the J point and ends with the onset of the T wave.
3. The normal ST segment is flat (isoelectric)
4. Elevation or depression of the segment by 1 mm or more above or below baseline (measured 0.08 seconds or 2 small squares past the J point) is considered abnormal.
5. ST elevation is a sign of myocardial injury as seen in AMI. It may also indicate coronary vasospasm (Prinzmetal's angina), pericarditis, and ventricular aneurysm.
6. ST depression is a sign of myocardial ischemia. Other common causes are left and right ventricular hypertrophy, left and right bundle branch block, hypokalemia, and the administration of certain drugs (digoxin, quinidine, and procainamide). Dig causes a sagging ST depression with a "scooped out" appearance.



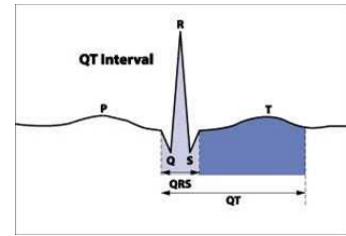
#### E. T wave

1. **Represents ventricular repolarization.**
2. T waves are really made up of two T waves. One for the epicardium and one for the myocardium. This is something a lot of people miss but it explains various EKG findings.
3. The normal T wave begins with a positive upward slope from the ST segment and ends when the deflection returns to baseline.
4. Normal T waves are rounded, asymmetric (the point is closer to the end of the wave than the beginning), positive in Lead II with an amplitude less than 5 mm.
5. Abnormal T waves may be symmetric and may be abnormally tall or flat, biphasic, or inverted.
6. The ST segment is a reflection of the speed (velocity) of the repolarization that peaks at the T wave. The faster the repolarization the higher the ST segment will be and the slower, the lower it will be.
7. The narrower the T wave, the more both the epicardium and myocardium are repolarizing faster.
8. Abnormal T waves are seen in myocardial ischemia, infarction, hypokalemia (flat), hyperkalemia (tall and peaked), pericarditis, ventricular hypertrophy, bundle branch block (BBB), and in the presence of certain drugs (digitalis, procainamide, quinidine, and phenothiazines).
9. The T wave gets wider with ischemia and infarct - and can get so wide as to look like tombstones. It can also get very tall when this happens as both the epicardium and myocardium become ischemic (transmural infarction).
10. While the process is acute (or happening now) repolarization is faster and the cells are changing to anaerobic metabolism. This causes elevation and hyperacute T waves... once the blood flows again and oxygen returns to the cells - it damages the cells. Some cells will start to repair themselves while others cannot be repaired. During this period, the cells do not work well and repolarization slows down. This causes T wave inversion (Nudell, 2011).



**F. QT interval**

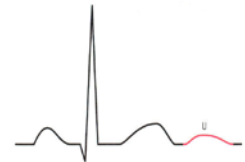
1. Represents the time between the onset of ventricular depolarization and the end of ventricular repolarization.
2. It is measured from the beginning of the QRS to the end of the T wave.
3. The length of the QT interval normally varies according to age, gender and heart rate.



- a. As HR increases, QT decreases.
- b. The normal QT should be less than  $\frac{1}{2}$  the distance between 2 consecutive R waves (called the R-R interval) when the rhythm is regular.
- c. A normal QT interval indicates that ventricular depolarization and repolarization have occurred within a normal amount of time.
- d. A short QT indicates an increase in the rate of ventricular repolarization and is not significant.
- e. The importance of QT measurements is to determine if it is prolonged. A long QT indicates a delay in ventricular repolarization. This lengthens the relative refractory period or vulnerable period of the cardiac cycle and predisposes people to life-threatening dysrhythmias (torsades de pointes).
- f. The most common causes of prolonged QT intervals include hypokalemia, hypocalcemia, **hypomagnesemia**, liquid protein diets, bradyarrhythmias, myocardial ischemia, AMI, LV hypertrophy, subarachnoid hemorrhage, hypothermia, hereditary long-QT syndromes, and the administration of certain drugs (quinidine, procainamide, disopyramide, tricyclic antidepressants, amiodarone, phenothiazines, flecanide, ibutilide, and sotalol).

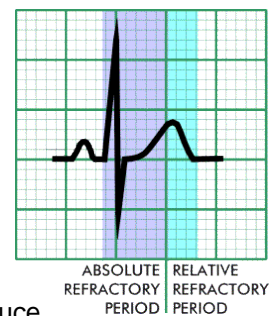
**4. U waves**

- a. Seen as a small upright deflection that may follow the T wave.
- b. Neither the presence or absence of this wave is considered abnormal.
- c. Thought to be part of the ventricular repolarization process.
- d. Normal U waves are small, rounded, less than 2 mm in height, and are deflected in the same direction as the T wave.
- e. They tend to be larger with slow heart rates and smaller with fast heart rates.
- f. Prominent U waves (taller than 2 mm) may be seen with LV hypertrophy, exercise, stroke, hypomagnesemia, hypokalemia, or in patients taking the same drugs that cause a prolonged QT interval. A prominent U wave also predisposes a patient to torsades de pointes.



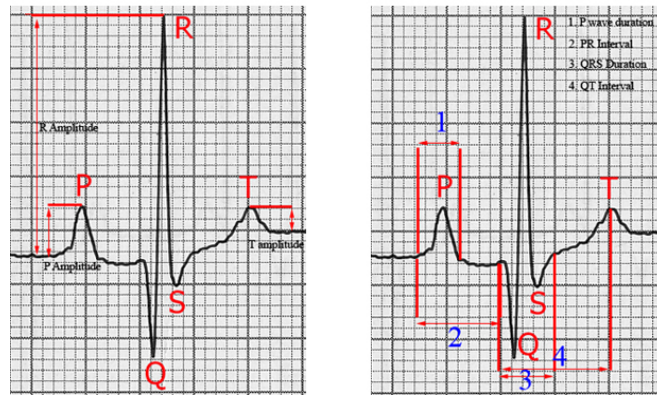
**G. Refractory periods**

1. Period of time when cells have been depolarized and not yet returned enough to a polarized state to accept another impulse.
2. **Absolute refractory period:** From beginning of QRS to the apex of the T wave. Time when stimulation will produce **no depolarization** at all.
3. **Relative refractory period:** Top of and downslope of T wave: Time when a sufficiently strong impulse stimulus (PVC) may produce



depolarization and repetitive firing (V-tach or V-fib). Also known as the **vulnerable period**.

4. **Supernormal period:** The period of time at the end of the T wave just before the cells have completed repolarization when cardiac cells will respond to a weak stimulus.

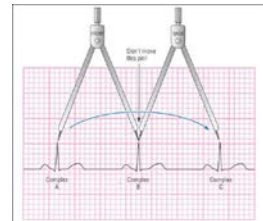


## VI. Rhythm strip analysis

- A. The cardiac rhythm can be identified by analyzing the waves in a consistent, systematic manner. Each step should be performed in sequence.

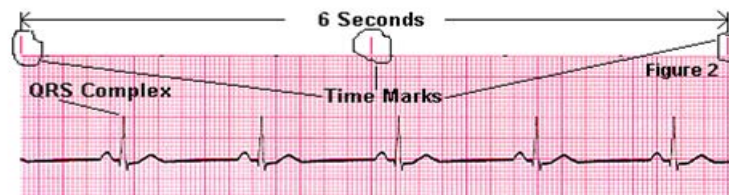
### B. Determine regularity

1. Starting at the left of the strip, mark a piece of paper above the first two R waves or place caliper points on the first two R waves. Then move the paper or calipers and compare the initial measurement from R wave to R wave across the entire strip.
2. Note any variations in R wave regularity.
3. If the rhythm varies by more than 0.12 seconds (3 small squares) between the shortest and longest R-R variation, the rhythm is considered irregular.
4. If irregular, look for a pattern to the irregularity
  - a. Regularly irregular - pattern to the irregularity
  - b. Occasionally irregular
  - c. Irregularly irregular - no pattern
  - d. Are any beats premature? (Ectopic beats)
  - e. Are any beats late? (Escape beats from a slower pacemaker)
  - f. Is there a general speeding or slowing of the rhythm?
  - g. Are there pauses?
  - h. Is there group beating? (Complexes come in groups then a pause – seen with Wenkebach pattern)

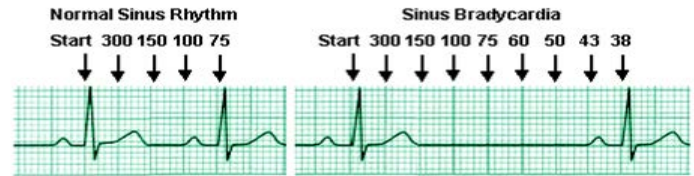


### C. Calculate the heart rate

1. This usually means the ventricular rate unless the atrial and ventricular rates differ. Then both must be counted.
2. If the rhythm is regular or irregular, use the **rapid rate or 6-second strip** calculation method. Count the R waves in a 6 second strip and multiply by 10.



3. If the rhythm is regular, use the **precise rate method**. Count the number of large boxes between 2 R waves and divide into 300.
- a. 1 large box between R waves = HR of 300
  - b. 2 large boxes = 150
  - c. 3 large boxes = 100
  - d. 4 large boxes = 75
  - e. 5 large boxes = 60
  - f. 6 large boxes = 50
  - g. 7 large boxes = 43
  - h. 8 large boxes = 38
  - i. 9 large boxes = 33
  - j. 10 large boxes = 30



4. You can count the number of small boxes between 2 R waves and divide into 1500 (number of small squares in a one minute strip) for a more specific rate.
5. A variation on this approach is called the triplicate method. Find a QRS that lands on a dark line. Going towards the right find the next QRS complex. If it landed on the next bold line, the HR would be 300, on the next, a rate of 150, 100, 75, 60, 50 etc. Each small square represents a different HR value. Use this rate when more familiar with ECG interpretation.
6. Do not rely on a digital heart rate reading on the ECG monitor or from the SpO<sub>2</sub> monitor. They vary greatly.

**D. P Waves**

- 1. Are they present or absent? Is the P - P regular or irregular?
- 2. Is there a P wave for each QRS? Are there more Ps than QRSs?
- 3. Do they come before or after the QRS?
- 4. Are they normal/upright or inverted?
- 5. Do they all look alike in size, shape and position?
- 6. A P wave of normal size, shape, direction, and PR interval usually indicates that the electrical impulse originated in the sinus node.

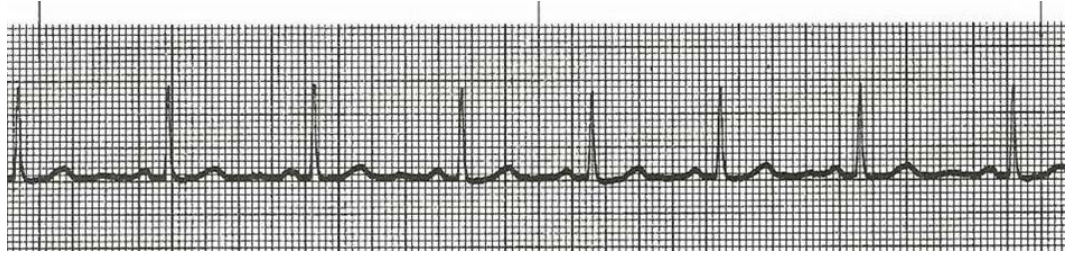
**E. PR interval (PRI)**

- 1. Measure each PRI on the strip.
- 2. Is it normal, short, or prolonged? (0.12 - 0.20 seconds or 3-5 small squares)
- 3. Is it constant (fixed) or variable? It should be relatively constant across the strip.

**F. QRS complexes**

- 1. Are they present and regular?
- 2. Preceded by a P wave or not?
- 3. Do they all look alike?
- 4. Measure from where the QRS complex leaves the baseline to the J point.
- 5. Count the number of small squares in this measurement and multiple by 0.04 seconds.
- 6. Normal: 0.04 to 0.10 seconds (1 to 2½ small squares)
- 7. Wide: 0.12 seconds or longer.





- G. When interpreting the strip, describe the basic underlying rhythm first, then add additional information, such as normal sinus rhythm with frequent premature ventricular contractions (PVCs) or Sinus rhythm with first degree AV block.
- H. When rhythm strips have premature beats, the premature beats are not counted in the rate calculation. Count the rate in the uninterrupted section. This is the underlying rhythm.
- I. When rhythm strips have more than one rhythm on a 6-second strip, rates must be calculated for each rhythm and note each rhythm.

VII. **Comments on the variability of ECG interpretation** from Dr. Paul Matera 2/6/08

- A. Non-ACS ECG changes from one ECG to the next can and have been documented and are significant ...changes occurring due to non-standard ECG lead placement, i.e., using trunk leads rather than limb leads, etc have caused both over and under diagnosis with the accompanying errant clinical diagnosis and unneeded treatment rendered including in erroneous AMI diagnosis
- B. During an ACS evaluation/treatment some of the more "drastic" changes that are seen are of the Q, R, ST/T variety, but that does not mean that many confounders, biases, and variables have not changed between ECG #1 and #2, etc. 3). These "numbers" all change from second to second, minute to minute during , for example, an ACS crisis, and require an experienced over-read to keep patients safe and getting the most appropriate care.
- C. The myocardium not only varies from one ECG to the next it also varies from one beat the next. Changes in perfusion, O<sub>2</sub> supply, O<sub>2</sub> demand, O<sub>2</sub> uptake, electrolyte availability, drug action/interaction, etc all change the resting potential of the myocardial cells. These also change the Na<sup>+</sup>/K<sup>+</sup>/Ca<sup>++</sup>/Mg<sup>+</sup>, ectopy, patient position, recent activity, influence from other systems, i.e., CNS where we see drastic ECG changes appearing like AMI/ischemia but are all in reflex to a large CNS insult (probably epi/nor-epi/serotonin mediated).

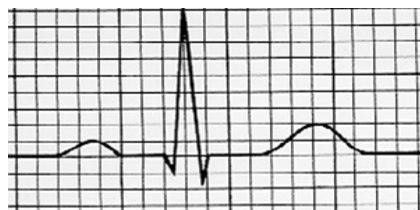**References**

- Bledsoe, B., Cherry, R.A., Porter, R.S. (2017). Electrocardiographic monitoring. In, Bledsoe et. al. (Eds), Paramedic Care Principles and Practice (Fifth Edition) (pp. 65-75; 157-159). NY: Pearson.
- Huff, J. (2002). *ECG Workout Exercises in arrhythmia interpretation* (4th ed.) (pp. 9-14, 15-23, 29-32, 39-45). Philadelphia: Lippincott.
- Hurst, J.W. (1998). Naming of the waves in the ECG, with a brief account of their genesis. *Circulation*, 98:1937-1942.
- Kligfield, P., Gettes, L.S., Bailey, J.J., Childers, et al. (2007). Recommendations for the standardization and interpretation of the electrocardiogram Part I. *Circulation*;115:1306-1324.



### Homework Questions

1. The Sinoatrial node is located in the: \_\_\_\_\_
2. The AV node is located in the \_\_\_\_\_
3. The bundle branches run down each side of the ventricular \_\_\_\_\_
4. The smallest branches of the conduction system that go to all the ventricular cells are the \_\_\_\_\_ fibers.
5. What is the intrinsic pacing rate of the SA node in an adult? \_\_\_\_\_
6. What is the intrinsic pacing rate of the AV node in an adult? \_\_\_\_\_
7. What is the intrinsic pacing rate of the ventricles in an adult? \_\_\_\_\_
8. **True or false:** The ECG provides a graphic record of the heart's stroke volume and CO.
9. What electrical activity does a P wave represent? \_\_\_\_\_
10. The P-R interval represents the time necessary for \_\_\_\_\_ depolarization and conduction of the impulse up to the \_\_\_\_\_
11. What electrical activity does a QRS complex represent? \_\_\_\_\_
12. What electrical activity does a T wave represent? \_\_\_\_\_
13. Waves that are not usually present, can be associated with electrolyte abnormalities, but that may be a normal finding are \_\_\_\_\_ waves.
14. On the drawing, label the P wave; Q wave; R wave; S wave; T wave; ST segment; PR interval; QRS complex:



15. A P wave of normal size, shape, direction, and PR interval usually indicates that the electrical impulse originated in the \_\_\_\_\_.
16. The PR interval is measured from the \_\_\_\_\_ to the beginning of the \_\_\_\_\_.
17. A normal P-R interval ranges between: \_\_\_\_\_ seconds.
18. A prolonged PR interval
  - A. measures 0.12 to .20 seconds.
  - B. indicates a delay in the AV node.
  - C. may indicate a bundle branch block.
  - D. is related to an increased risk of sudden death.
19. A QRS complex is measured from \_\_\_\_\_ to the point where the last wave of the complex begins to flatten out or become more horizontal. This junction between the QRS and the ST segment is known as the \_\_\_\_\_ point.

20. **True or false:** All three waves (Q, R, and S) must be visible to discern a QRS complex.
- True or false:** More than one R or S wave may be present in one QRS complex.
21. A normal QRS duration ranges between: \_\_\_\_\_ seconds.  
What could cause an abnormally long QRS duration?  
\_\_\_\_\_  
\_\_\_\_\_  
\_\_\_\_\_
22. The normal ratio of P waves to QRS complexes is: \_\_\_\_\_
23. The vertical lines on the ECG graph paper measure seconds of \_\_\_\_\_
24. Each small square of ECG graph paper represents \_\_\_\_\_ seconds.  
Therefore, each  $\frac{1}{2}$  of a small square represents \_\_\_\_\_ seconds.
25. Each composite of 5 small squares noted by a darker line (big square) represents \_\_\_\_\_ seconds.
26. Time interval markings on the top of ECG paper are placed at \_\_\_\_\_ second intervals.
27. The horizontal lines measure the \_\_\_\_\_ or \_\_\_\_\_ of the waveforms in mm.
28. Any waveform above the isoelectric line is considered a **positive / negative** deflection.  
Any waveform below the isoelectric line is considered a **positive / negative** deflection.  
A waveform having both an upright and a downward component is called \_\_\_\_\_  
An electric current flowing toward the positive pole will produce a \_\_\_\_\_ deflection on the ECG. An electric current flowing away from the positive pole will produce a \_\_\_\_\_ deflection on the ECG.
29. The size of the wave deflection will depend on the \_\_\_\_\_ of the electrical current flowing toward the individual pole.
30. The period of time during the cardiac cycle when the cardiac cells may not be depolarized by any electrical stimulus is called the \_\_\_\_\_ refractory period.  
The period of time during the cardiac cycle when the cardiac cells have repolarized sufficiently to respond to a strong electrical stimulus is called the \_\_\_\_\_ refractory period or \_\_\_\_\_ period.  
The period of time at the end of the T wave just before the cells have completed repolarization when cardiac cells will respond to a weak stimulus is called the \_\_\_\_\_ period.
31. Depolarization that occurs from cells other than the normal pacemaker cells are called \_\_\_\_\_ beats.
32. The type of leads placed by Paramedics when obtaining a rhythm strip consist of a positive and a negative pole, and are therefore called: \_\_\_\_\_.
33. The (white) right arm (RA) lead is attached to an electrode placed below the \_\_\_\_\_

34. The (black) left arm left arm (LA) lead is attached to the electrode placed below the \_\_\_\_\_
35. The (red) left leg (LL) lead is attached to the electrode placed on the \_\_\_\_\_
36. Patients should typically be monitored in Lead \_\_\_\_\_
37. If leads do not have good contact with the skin, distortions of the ECG tracing may occur that are called \_\_\_\_\_
38. Electrodes should be inspected for:  
\_\_\_\_\_  
\_\_\_\_\_
39. **True or false:** Electrodes should be placed over bony prominences to enhance conduction of the electrical tracing.
40. What can be done to enhance lead adhesion if a patient has thick chest hair?  
\_\_\_\_\_
40. Muscle tremors, shivering and loose electrodes can cause erratic deflections on the ECG called
- |               |                                |
|---------------|--------------------------------|
| A. anomalies. | C. aberrant conduction.        |
| B. artifacts. | D. FLBs (funny looking beats). |
41. If electrical equipment is in use in the ambulance patient compartment, equipment is improperly grounded, or wiring is loose or exposed, you will see a unique artifact that looks like a continuous series of fine, even, rapid spikes known as \_\_\_\_\_
42. How should a-PM determine regularity of an ECG tracing?  
\_\_\_\_\_  
\_\_\_\_\_
43. A rhythm is irregular if it varies by more than \_\_\_\_\_ seconds or \_\_\_\_\_ small squares between the shortest and the longest R wave variation.
44. When counting heart rate using the rapid rate method, one should count the number of R waves in \_\_\_\_\_ seconds and multiply by 10.
45. All P waves should be almost identical in \_\_\_\_\_, \_\_\_\_\_, and \_\_\_\_\_.
46. To measure the PR interval, count the number of small squares from the beginning of the P wave until the beginning of the QRS and multiply by \_\_\_\_\_ seconds.
47. What should be analyzed when interpreting all rhythm strips?  
\_\_\_\_\_  
\_\_\_\_\_  
\_\_\_\_\_  
\_\_\_\_\_  
\_\_\_\_\_