Chest and Abdominal Trauma Case Studies

NWC EMSS November 2015 Continuing Education

Susan Wood, RN Paramedic

The Saving of the President

Produced by: Frank Kavanaugh, MD

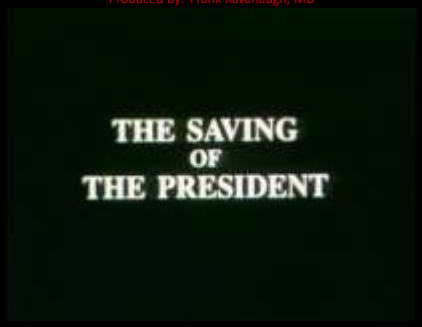

Goals for Today

Review of:

- Different etiologies of shock specifically how it relates to chest & abdominal trauma
- Immediate life threats surrounding pts sustaining chest & abdominal trauma
- Identify injury based on blunt vs. penetrating trauma

Before going any farther…

Write down one question that still remains unclear for your individual practice when encountering trauma patients, whether related to chest and abdominal injury or generally speaking.

What is so shocking?

All forms of shock are due to failure of one or more of the 3 separate but related factors necessary to maintain perfusion.

Individuals must have:

- **Adequate pump**
- **Circulating blood volume (with oxygen carrying capacity)**
- **Intact vascular container**

Shock…what's the issue?

Shock is *classified by its primary etiology*, **even though** multiple dysfunctions often occur in response to the primary insult.

Pump	Volume
Container	Obstruction

Pump

Blunt cardiac injury

Container

Deceleration injury

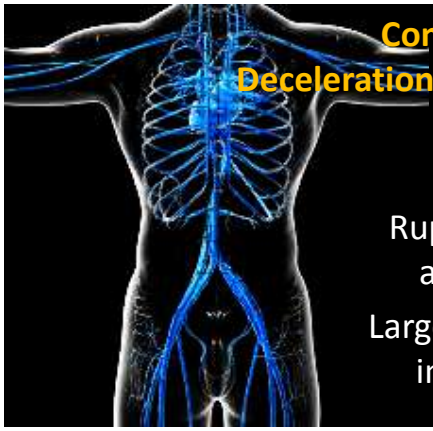

Ruptured aorta

Large vessel injury

Volume

Hemothorax

Obstructive shock is commonly seen in association with…

Chest trauma

Jeopardy question:
What other mechanism can results in obstructive shock?
Pulmonary Embolus

What is the mechanism?

- Blunt
- Penetrating
- Compression

In which part of the assessment should these injuries be found?

Primary

B=Breathing

What is the common complaint with any chest injury?

Respiratory distress

Unchanging Priorities

- Airway patency
- Breathing/gas exchange
- Circulation/cardiac status
- Disability – neuro life threat
- Environment/expose

Avoid **HYPOXIC** injury

Deceleration injury

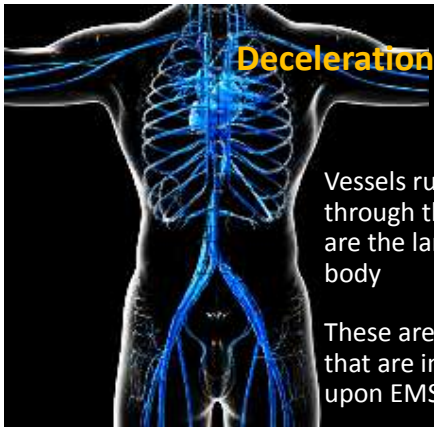

Vessels running through the chest are the largest in the body

These are the pts that are in arrest upon EMS arrival

A deceleration injury causing a ruptured large vessel quickly leads to a volume issue

Before EMS is ever on the scene

Volume

Hemothorax

>1500 mL blood in pleural space

Pleural space can hold entire blood volume

SOP: ITC p. 37

Permissive hypotension to maintain perfusion

Blunt vs.

Penetrating

Pump

Often in trauma pts cardiac monitoring is an after thought which is not acceptable practice

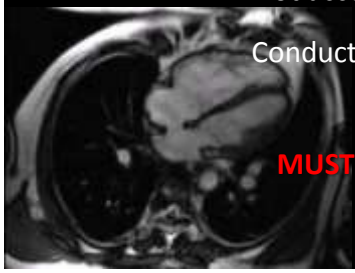

Conduction deficit from contusions

MUST be on a cardiac monitor

Kine-what?

Trauma:

"Transference of energy from some external force to the human body which exceeds the tensile force/resiliency of the body causing a structural or physiologic alteration" (Halpern, 1989).

Kinematics:

Relationship between speed, mass, vector direction & physical injury

the study of motion exclusive of the influence of mass & force

Both are traumatic but….

Case Studies

Case 1:
Dispatched to a 2-car MVC with head on collision
(posted speed 40 MPH)

- Unrestrained driver / + steering wheel deformity
- A & O X 3 but restless & agitated
- C / O severe chest pain & difficulty breathing

Assessment

A: Patent

B: RR fast; labored w/ asymmetric expansion + accessory muscle use; no paradoxical movement
BS absent on L, diminished on R
No open wounds; trachea midline
RA SpO_2 86%; $EtCO_2$ 27

C: No radial pulse; carotids fast, weak & thready + JVD

D: E=spont, V=oriented, M=to command; PERL, abrasion to L chest

Identify life threats found in primary assessment & treat

Patent airway

Respiratory distress

Perfusion status altered; no palp radial pulse

*Mental status remains intact

What MOI is responsible for ~70-80% of blunt chest trauma?

MVC

Followed by:
Falls
Sports related injury
Crush injury

Blunt

Direct compression

Fracture of solid organs
Blowout of hollow organs

Deceleration forces

Tearing of organs and blood vessels

Blunt

- Results from energy exchange between an object & human body
- Occurs when a body area is struck by, or strikes, an object
- Higher mortality
  - Injury often hidden; evidence of injury very subtle or absent

WHICH IS MOST LIKELY SUSPICION BASED ON PRESENTATION?

Pneumothorax
Tension Pneumothorax
Why?

Classic clinical findings?

Chest pain
Extreme dyspnea; ↑ WOB
Anxiety, tachypnea, hypoxia
↓ BS on affected side
↑ HR; ↓ MAP; narrowed PP
Resistance to BVM ventilations
+ JVD (- hypovolemia)

What information is needed to confirm suspicion?

Vital Signs

Why?

How can you tell the difference between a pneumothorax & tension pneumothorax ?

(both have absent breath sounds)

Tension pneumothorax

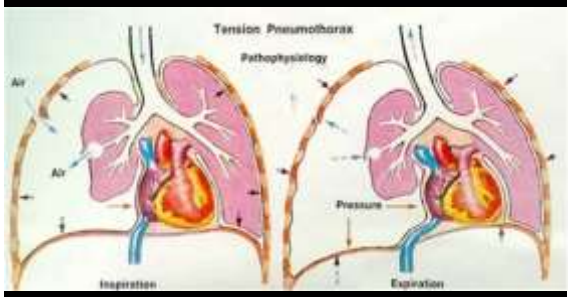

It starts with a simple pneumothorax

Simple Pneumothorax

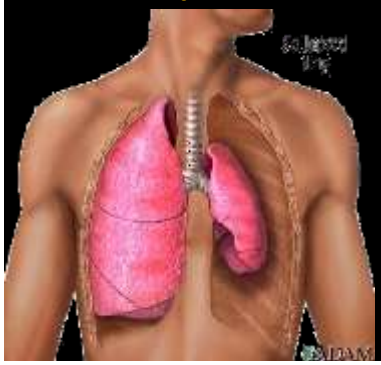

Collection of air into the pleural space through an injury to the chest wall

Many underlying etiology – medical and trauma

But it doesn't stop there…

Defect in chest wall acts as one-way valve

Air is allowed to enter upon inspiration, but not escape on exhalation

Each breath further deflates the lung & collapses

Tension PTX is often caused by care provider over/hyperventilating

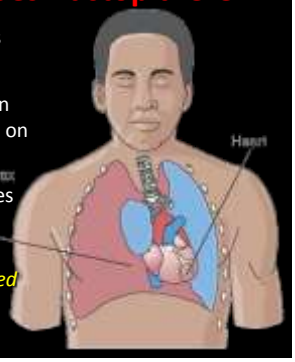

Why so much pressure?

https://www.youtube.com/watch?v=i-sZzZ4TMnY

Secondary Assessment

VS: BP 84/60, P 116, R 24

Head to toe

After identification and treatment of life threat

So, what intervention should be done after identification of a life threat?

Pleural needle decompression…

Only 3 were done in the field this last year, all with proper indication

Low frequency high stress situation

Let's review

PBPI stats

What landmarks must you find?

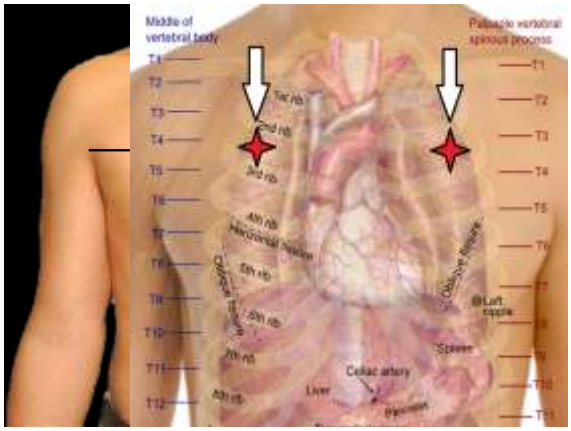

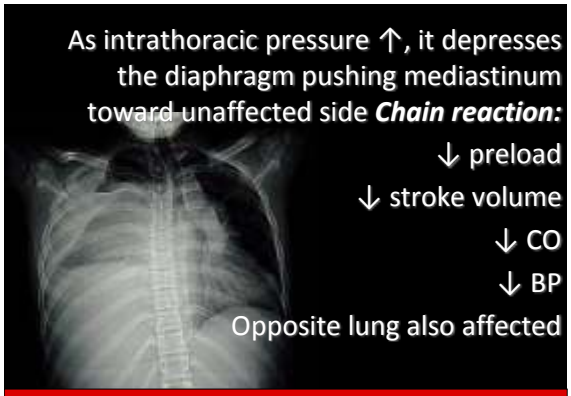

As intrathoracic pressure ↑, it depresses the diaphragm pushing mediastinum toward unaffected side ***Chain reaction:***

↓ preload

↓ stroke volume

↓ CO

↓ BP

Opposite lung also affected

*This is **obstructive shock**!*

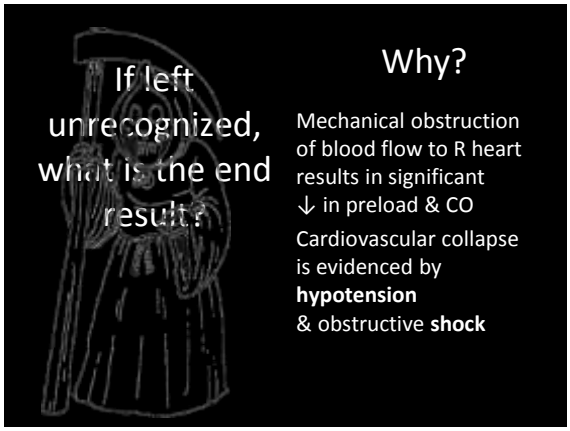

If left unrecognized, what is the end result?

Why?

Mechanical obstruction of blood flow to R heart results in significant ↓ in preload & CO

Cardiovascular collapse is evidenced by **hypotension** & obstructive **shock**

What should happen after the needle penetrates the pleural space?

Release pressure (tension)
Relieve acute distress
Improve ventilations
Re-establish venous return
(CO, pulses, BP)

What are the risks and complications associated with procedure?

What if there is no improvement?

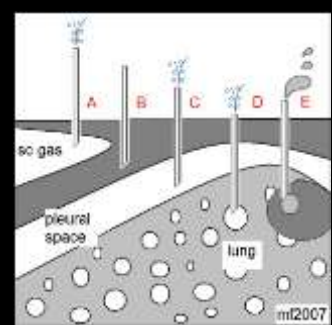

Why is the mid-axillary site discouraged?

Diaphragm can rise to 4th or 5th ICS when pt is supine

Needle may penetrate liver or spleen

Case 2
Dispatched for an adult who fell

- Neighbor sees pt (50 M) lying on cement driveway supine outside home, calls EMS
- Ladder on ground outside 2 story (~20 ft.) family home; bushes in front appear damaged
- Upon arrival, EMS finds a person as stated with blood from L forehead; 10" diam of blood on ground
- Moaning; localizes pain & appears in distress

Assessment

A: Gurgling sounds noted in airway w/ bloody secretions

B: Breathing faster than normal, shallow and labored effort (diminished BS on L side)

C: + fast, reg pulse; radials are weak. Cap refill 3 sec

D: Eyes open to pain, incomprehensible sounds made and localizes to painful stimuli. Pupils PERRL; bG 86

What is the concern?

Multi-system trauma

Head injury yes; but also breathing is affected

Any add'l info does EMS obtain in 1° survey?

- Capnography (28, square)
- SpO2 (91%)
- Will move all extremities to command except L foot (a deformity is noted)

Identify life threats

The purpose of the 1° survey is to identify those injuries that are life threats

What interventions have been done?

- Suction & maintain airway
- Breathing issue (↓ BS on L)
  - Determine need for oxygen
- Alteration in perfusion (faint radial pulse)
  - Consider IVFs after VS

Now what?

Secondary assessment

VS: BP 94/64, P 116, R 24

Head to toe

Head: airway clear w/ suctioning

Pupils: PERL, no bruising to face

Neck: - JVD, trachea midline

Chest: abrasion & tenderness L lat area; + distress; + crepitus to palp w/paradoxical mvt

Abdomen: abr. LUQ/L flank area; moans to palp

Pelvis: unremarkable

Ext: L LE w/deformity; otherwise + movement x 4

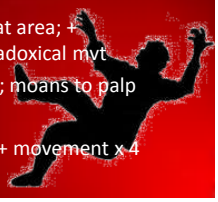

The eye does not see and the hand does not feel what the mind does not think of…

True or False

Individuals who sustain blunt chest trauma do not usually have to be admitted to the hospital?

False: Accounts for 1/3 of all trauma admits

Often associated with multi-system injury

What ALL is going on?

- Multi-system trauma
- Head injury

Closed chest injury

- Flail
- Assessment findings: paradoxical movement

By definition, a flail consists of…

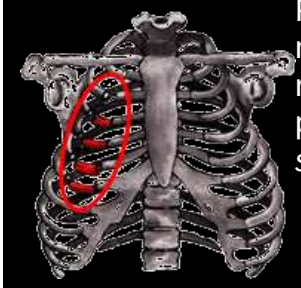

Fracture of 3 or more adjacent ribs in 2 or more places = *mobile segment*

Possible injury location?

Anterior, posterior, or lateral

Separation of sternum from adjacent broken ribs or costochondral joints: sternal flail chest

Free floating chest wall segment palpated or observed as paradoxical movement

When should a flail be recognized?

Primary assessment

What causes fatigue with a flail chest?

Muscle tightening

Increased effort to breathe

Treatment?

Assist with breathing

How?

CPAP (if pt capable of following instructions)

BVM (if altered mental status)

The significance…

Flail chest, the most severe form of blunt chest wall injury with mortality rates of 10-20%

Pulmonary contusion occurs in 30-75% of blunt thoracic trauma

The Eastern Association of the Surgery of Trauma, 2006 *EAST* guidelines

Flail

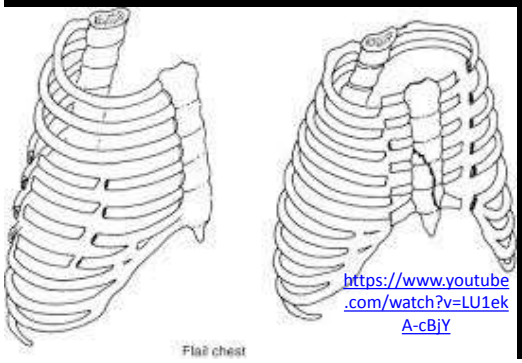

https://www.youtube.com/watch?v=LU1ekA-cBjY

Goal

CPAP

Ensure oxygenation

Prevent hypercarbia

"Obligatory mechanical ventilation should be avoided…and C-PAP should be considered in alert pts with good ventilatory effort (East, 2006)

Let's Review

Positive pressure (CPAP) "splints" lower airways & keeps alveoli open

Prevents alveolar collapse (atelectasis)

Less energy used to open them with next breath

Stops fluid alveoli

Contraindications

Pneumothorax

Only going to be recognized through proper assessment

MUST listen for breath sounds throughout secondary and ongoing assessments

MUST reassess VS frequently checking for **hypotension (SBP<90)**

BREAK

Hang in there…

Case 3

- EMS is called to a house for an adult with chest pain from a penetrating injury.
- PD is on scene stating that the scene is safe and that there was an attempted home burglary in which the burglar stabbed the homeowner in an attempt to escape scene.
- Pt states that his chest feels like a burning sensation and respiratory distress.

Assessment

A: Patent, able to speak

B: RR faster than nl; shallow & labored

BS diminished B; + open wound to slightly L of center of chest; trachea midline

RA SpO_2 89%; $EtCO_2$ 30

C: faint radial pulse becoming non-palp w/ inspiration; carotids fast, weak & thready

+ JVD; skin dusky, cool & moist. No uncontrolled hemorrhage but + bubbling to chest wound

D: E=spont, V=oriented, M=to command; PERL, abrasion to L chest

Open chest injury

How can a chest be "open?"

- An object can pass through the wall from the outside or a fractured and displaced rib can penetrate the chest wall from within
- Injury can occur to the heart, lungs or great vessels when penetration to the chest wall occurs

Assessment

EMS finding a wound to the chest wall in which there may (*or may not*) be a characteristic "sucking" sound associated

The pt may be SOB or gasping for air

Identify treatment modalities

Treatment

What ultimately needs to be done for an open pneumothorax?

Maintain adequate ventilation w/ open airway

How is this accomplished?

Apply an occlusive dressing to seal the wound

Administer oxygen as needed

Identify shock

Transport decision

Penetrating

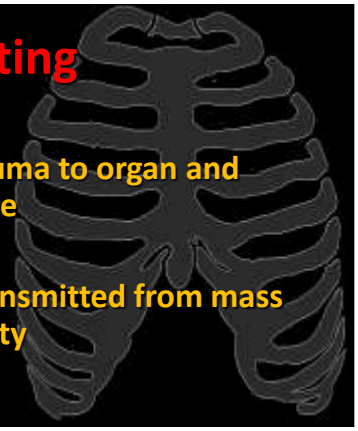

Direct trauma to organ and vasculature

Energy transmitted from mass and velocity

Why can breath sounds be absent on both sides?

Air enters thoracic cavity through wound – must have negative pressures & intact pleural membranes to cause gas movement through tracheobronchial tree

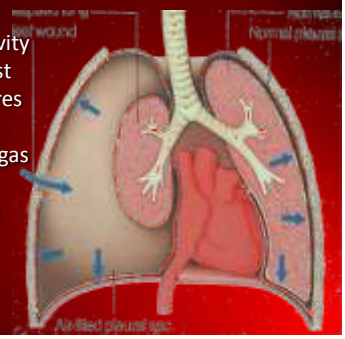

What makes this happen?

Ventilation/perfusion mismatch

Air may exit wound during exhalation producing frothing or bubbling at the site

Air may be allowed in but not out increasing pressure in pleural space -possible mediastinal shift

Direct lung injury possible

Patient dies from inadequate ventilation and NO GAS EXCHANGE

Remember…

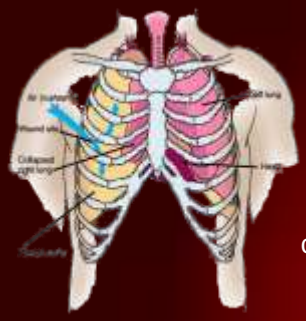

If wound approximates ⅔ tracheal diameter, most air will move through chest wall defect, *NOT* through trachea

On to…what is next?

Secondary assessment

Pt c/o "not being able to catch his breath"

BP: 96/72, P: 136, R: 26 and labored

SpO2: 88% RA; EtCO2: 30

Airway remains open, no DCAP-BTLS-TIC PMS to head or neck

Chest w/ an open wound, blood bubbly w/resps

Abdomen and pelvis unremarkable

What needs to be done?

Needle decompression?

How about closing the hole that's already there while allowing the air to escape that has already started to collect?

How is this done?

Convert open pneumothorax to closed

Apply an occlusive dressing
- vaseline gauze
- defib pad
- commerical device

Monitor VS, ventilatory & circulatory status

Assess for JVD after application

Continue with ITC

SOP p 41

IF S & S of tension PTX:

temporarily lift side of dressing

to allow air release

recover wound

Assess need to Decompress only *IF NO* improvement following removal of dressing

Because this stab wound was on the L chest close to midline, what additional finding is this pt at risk for?

What if the BP showed a narrow PP & muffled heart tones?

Cardiac tamponade

Small penetrations in pericardium seal from fatty tissues or formation of clots

Once sealed, blood to collect putting vena cavae & RA

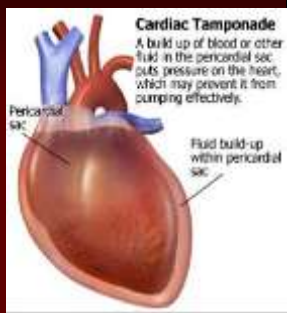

Classic clinical findings?

Beck's triad
- narrowed PP
- JVD
- muffled heart sounds

Looks like cardiogenic shock

BS present (unless other accompanying injury

Case 4
Restrained driver MVC

- EMS is called to the expressway for a frontal impact MVC
- 15-20" metal intrusion in at dash
- w/s broken & steering wheel bent
- Awake, responding to verbal stimuli & guarding chest, splinting when he breathes

Assessment

- A: patent, able to speak
- B: Dyspneic; RR rapid, shallow & labored w/redness & abrasions to chest
  SpO_2 90%, capnography 34
- C: + equal radial pulse, rapid & thready. Skin pale, cool & clammy. No external bleeding noted
- D: GCS = 14. Pupils PERL 3 mm; responding to verbal stimuli

Injury from direct blow to the chest

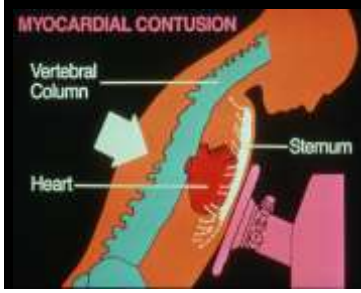

Whatever the MOI

Blunt cardiac injury

Mortality 8-20%

MVC: 20-35 MPH can cause cardiac injury w/o obvious chest wall injury

Forces: Compression, acceleration/deceleration, intra-abdominal cavity compression

Assessment

CC: retrosternal chest pain or SOB
typically sharp, well localized
may mimic ischemic pain
Hard to distinguish from chest wall pain

Inspect for ecchymosis on anterior chest
S/S hemodynamic instability
& cardiogenic shock
May be asymptomatic

Dysrhythmias: 90% present at impact
Death in field caused by VT or VF
Anticipate: ST, PVCs, VF, AF, A-flutter; PEA may be present
Frequently resolve by hospital arrival
May have ↓ CO

Assessment should include

- Changes in mental status
- SBP < 100 mmHg
- Absent/thready peripheral pulses
- Pulsus paradoxus
- JVD
- Muffled heart sounds

What's indicated?

O2 based on need
ECG monitoring: 12-L
IVF to maintain BP to what in accordance w/ SOP?
How should hypotension be treated?
What should be given if dysrhythmias occur?

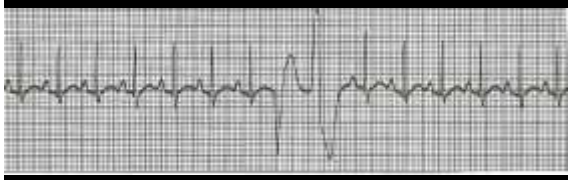

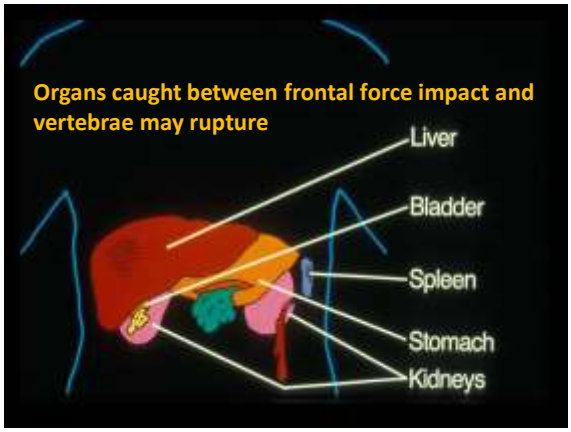

Secondary Assessment

VS:
- BP 92/50, P116, RR 26 & shallow

HEENT:
- unremarkable; trachea midline, no JVD

Chest:
- contusion over sternum on chest wall w/ pain; ECG ST w/ multi-focal PVCs

Abdomen:
- soft & non-tender

Skin:
- Pale, cool, diaphoretic

Neuro:
- GCS 14; PERL; SMV intact x 4 w/ pain 9/10

Chest Trauma

Pneumothorax
- Simple
- Open
- Tension
- Hemothorax

Flail

Cardiac tamponade

Whatever the problem…find it and stabilize it!

Abdominal injuries

In what year was it deemed mandatory to have automatic restraint systems in cars?

Restraints include: seat belts, shoulder straps, child safety seats, and airbags.

1990

Jeopardy question

Frequent cause of preventable death

Assume w/ deceleration MOI & penetrating torso wounds

High index of suspicion for abdominal injury

Blunt abdominal trauma

SUBTLE

Mortality < 46%

High (75%) incidence of other injuries

Solid organs more likely to be injured

Contributes to 25% of trauma deaths

Blunt vs. penetrating

Blunt injury is the usual MOI ~60% of the time ***except*** in urban situations in which penetrating reigns at 60-80%

Name that quadrant!

RUQ
Colon
Gallbladder
Duodenum
Adrenal glands
Liver
Appendix
Ureter
Kidney
Ovary

RLQ
Appendix
Ureter
Kidney
Ovary
Colon
Uterus
Fallopian tube
Pancreas
Spleen
Colon
Gallbladder
Duodenum
Uterus (if enlarged)
Fallopian tube
Adrenal glands

LUQ
Liver
Pancreas
Spleen
Colon
Adrenal glands

LLQ
Kidney
Ovary
Colon

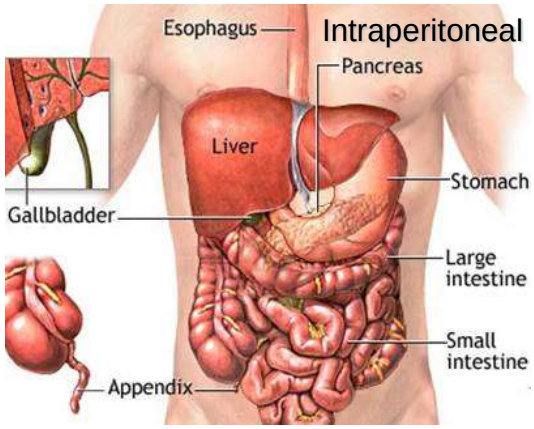

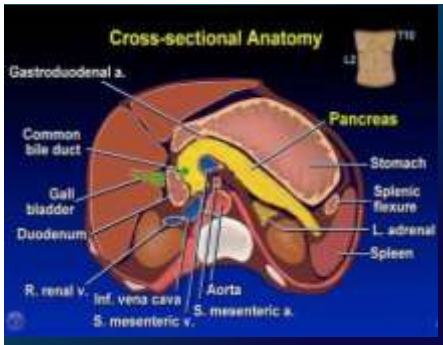

Cross section of the upper abdomen at the level of the pancreas

Retroperitoneal organs

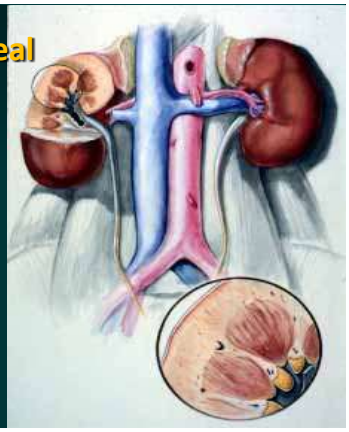

Held in place by mesentery

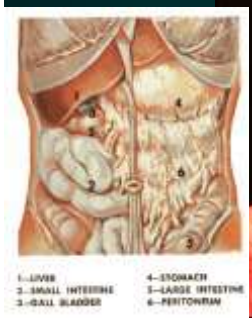

Interconnected relationship

Potential for great injury

Assessment Goals

Identify clinically evident life threats

Discover subtle signs of trauma through careful observation, continuous monitoring, serial exams

Case 5

50 restrained driver single vehicle crash drove off the road & laterally hit into a tree posted speed 40 MPH

Vintage car w/ lap belt only; patient found slumped sideways in to center of the vehicle, pt. moaning

Primary Assessment

A: patent

B: labored; rapid rate. BS normal & equal B

C: Radial pulses rapid & weak; skin pale & cool to touch

D: eyes closed; responds to verbal stimuli by moaning, not moving extremities to command. Pupils PERL, sluggish to respond

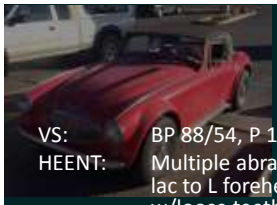

Secondary Assessment

VS:	BP 88/54, P 110, R 24
HEENT:	Multiple abrasions to lateral head w/ lac to L forehead-bleeding. Mouth w/loose teeth; bleeding. Trachea midline; No JVD.
Chest:	no injury noted w/ = expansion; no paradoxical mvt. ECG: ST w/ PVCs
Abdomen:	point tenderness to palp to B LQs; + guarding
Ext:	mult. abrasions; no entrapment or ext. needed

Greatest concerns for injury?

Head

Spine

B LQ abdomen

Primary concern?

Poor perfusion

Hypotension

Internal injury not seen!

Treatment Plan

Transport decision?

Level One TC

Why?

GCS < 13 and hemodynamically unstable

Ultimate Goal

Manage hypotension to maintain adequate perfusion

If an adult is hypotensive with blunt trauma, how much IVF should be infused?

Just enough to maintain SBP of 90 unless head trauma

Signs and Symptoms of Abdominal Injury

coughing up blood/vomiting blood, nausea, vomiting

rapid/shallow breathing

distended abdomen, tender

diffuse pain

rapid pulse

low blood pressure

shock

prefers to lie still with legs

Chest and abdominal injuries

In relation to traumatic injury, is often associated with multisystem injury.

The significance of MOI helps to predict patterns of injury.

Never under-estimate the need for complete & thorough assessments.

You will never find what you never think to look for when assessing injury in trauma patients.

Did we answer your questions today?